



A primary intravascular synovial sarcoma causing deep-vein thrombosis and pulmonary embolism in a 20-year-old woman

M. Schreiner Dr med,^{*†} W. Sanad Dr med,^{*} B.M. Pfitzner Dr med,[‡] G. Baumann Prof Dr med,^{*} and F. Knebel PD Dr med^{*}

ABSTRACT

Primary intravascular synovial sarcoma is a rare malignancy with only a few cases documented in the literature. On presentation, this tumour usually resembles a deep venous thrombosis (DVT) or pulmonary embolism (PE). Here, we report the case of a 20-year-old woman complaining of shortness of breath who had a history of DVT 6 weeks before presentation at our institution.

Vascular ultrasound detected a suspicious mass in the right groin, which was identified as a monophasic synovial sarcoma by surgical biopsy. The tumour extended from the right superficial femoral vein into the common iliac vein, profound femoral vein, and great saphenous vein. It caused PE with near-total occlusion of the right pulmonary artery. After initial treatment on the cardiac intensive care unit, the patient was referred to the oncology department for neoadjuvant radiochemotherapy with doxorubicin–ifosfamide according to the Interdisziplinäre Arbeitsgemeinschaft Weichteilsarkome [Interdisciplinary AG Sarcomas] protocol and surgical resection of the tumour.

No signs of tumour recurrence were found during the subsequent course of the disease, but the patient died from treatment complications approximately 15 months after initial presentation. This case underlines the importance of screening for malignancies even in young patients presenting with DVT or PE. We also recommend whole-leg compression ultrasonography in patients with suspected DVT or PE (as opposed to venography or simple four-point ultrasound examination in the groin and popliteal fossa) to detect possible underlying causes for thrombosis.

Key Words Synovial sarcoma, intravascular tumours, deep-vein thrombosis, pulmonary embolism

Curr Oncol. 2015 Oct;22(5):e387-e390

www.current-oncology.com

INTRODUCTION

The incidence of venous thromboembolism rises exponentially with age¹. But even in young patients, serious venous thromboembolism is not uncommon. A German study showed a pulmonary embolism (PE) incidence of 11 per 100,000 in the female population 10–29 years of age, and 6 per 100,000 in the male population 10–29 years of age².

Diagnostic strategies for PE usually include clinical probability scores, testing for D-dimer, echocardiography, and computed tomography or ventilation-perfusion scintigraphy³. Ultrasonography of the lower limbs is less important for making the diagnosis, because it detects deep vein thrombosis in only 50% of patients with manifest PE⁴. However, ultrasonography of the lower limbs is crucial in detecting anatomic anomalies leading to deep venous thrombosis (DVT) and embolism. Ultrasonography is readily available in most settings and easy to perform.

In the present case, the findings of a vascular ultrasound study led to the cause of venous thromboembolism in a 20-year-old.

CASE DESCRIPTION

A 20-year-old woman presented at our emergency department with progressive shortness of breath and pleuritic chest pain for about 3 days. She had presented at another hospital 6 weeks earlier with pain in the right thigh, where she was diagnosed with multilevel DVT of the right thigh. Duplex ultrasonography had revealed a clot extending from the superficial femoral vein to the external iliac vein and profound femoral vein. A “nodule” had also been described originating from the proximal superficial femoral vein, which had been interpreted as “clotted venous ectasia.”

Initial treatment had been certoparin, followed by rivaroxaban 20 mg once daily. No other illnesses were present, and no other medication was taken. A pregnancy test

Correspondence to: Fabian Knebel, Charité–Universitätsmedizin Berlin, Medizinische Klinik m.S. Kardiologie und Angiologie, Charité Campus Mitte, Charitéplatz 1, Berlin 10117 Germany.
E-mail: fabian.knebel@charite.de ■ DOI: <http://dx.doi.org/10.3747/co.22.2315>

was negative. No family history of DVT or PE was present. An activated protein C resistance ratio of 1.7 suggested heterozygous carrier status for the factor V Leiden mutation.

Despite anticoagulant treatment, the patient's medical history quickly led to a suspected diagnosis of PE. On computed tomography, we found an embolus with near-total occlusion of the right pulmonary artery and extension into segments 4, 6, 8, 9, and 10. The patient was hemodynamically stable, and no signs of right ventricular dysfunction were found on echocardiography. We therefore decided against thrombolysis. The patient was admitted to our intensive care unit and treated with intravenous heparin (adjusted to a partial thromboplastin time of 60–90 seconds).

Subsequent duplex sonography found a thrombus in the right thigh reaching from the distal superficial femoral vein to the common iliac vein, and thrombotic material in the profound femoral vein and the great saphenous vein. We also found a mass in the right groin measuring about 3×4.5 cm which compressed the femoral vein (Figure 1). Arterial Doppler signals could be recorded inside the lesion.

The patient confirmed that she had felt occasional pain in the right leg for about 12 months and had noticed a slowly growing lump in the right groin for about 6 months. The lump had been interpreted as a “muscle swelling” by the family doctors she had seen, and she had been given analgesic medications for it. The differential diagnosis at this time included arteriovenous malformation with thrombus, and sarcoma.

For further differentiation of the mass, magnetic resonance angiography and computed tomography were performed (Figure 2). A neoplastic structure was shown extending from the superficial femoral vein into the common iliac vein, profound femoral vein, and great saphenous vein. Additionally, thrombotic material was found attached to the neoplasm in the common iliac vein. No enlarged lymph nodes were found.

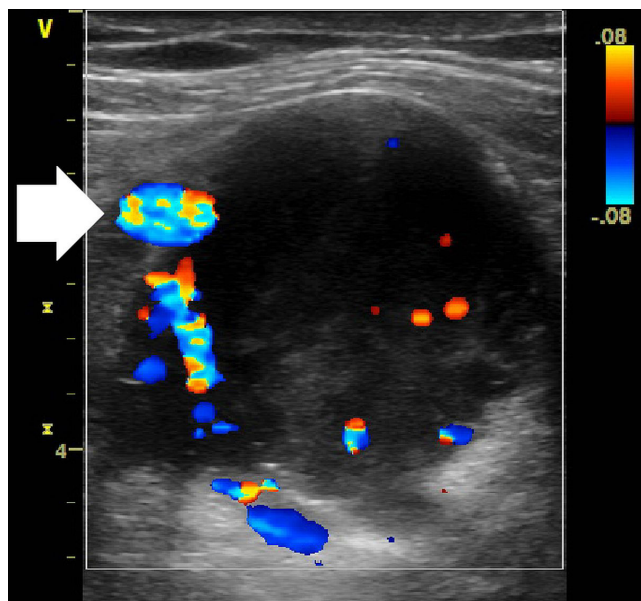


FIGURE 1 Duplex sonography, axial view, shows the right common femoral artery (arrow). A large circular mass with signs of arterial vascularization is found where the femoral vein is expected.

To reach a definitive diagnosis, open surgical biopsy was performed. A blueish tumour approximately 3.5×5 cm embracing the femoral vessels was dissected. A highly vascular piece of tissue was biopsied and sent to frozen-section analysis, which showed a mesenchymal neoplasm. The final pathologic diagnosis revealed a monophasic synovial sarcoma with characteristic *SYT1–SSX2* translocation t(X;18). Computed tomography of abdomen and pelvis did not find metastatic disease.

On day 13 after admission, the patient was referred to our oncology department for neoadjuvant radiochemotherapy and surgical resection of the tumour. Throughout the stay on the intensive care unit, the patient remained hemodynamically stable. Shortness of breath was resolved upon referral.

Considering the involvement of large vessels and the desire for limb-sparing surgery in a young patient, a decision for neoadjuvant radiochemotherapy was made. After informed consent, the patient was included in the Interdisziplinäre Arbeitsgemeinschaft Weichteilsarkome [Interdisciplinary AG Sarcomas] registry study and received 4 cycles of doxorubicin (60 mg/m² on day 1) and ifosfamide (3 g/m² on days 1–3). Cycles were repeated every 3 weeks. Chemotherapy was followed by radiation therapy to the tumour bed using a fractionation scheme of 5×1.8 Gy weekly (total dose: 50.4 Gy). On days 1–2 and 22–23 of the radiation course, the patient received ifosfamide 3 g/m².

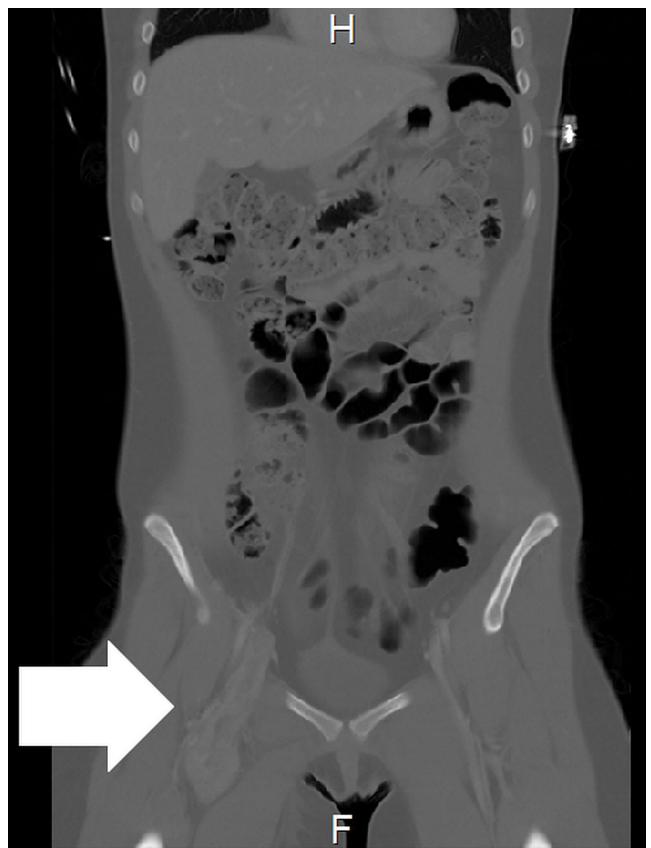


FIGURE 2 Computed tomography image, coronal view, shows a neoplastic mass (arrow) growing inside the right femoral and iliac vein.

After neoadjuvant radiochemotherapy, the tumour was completely resected with a wide margin. Regional lymph nodes proved to be free of disease. The femoral artery and vein had to be removed; they were replaced with a polytetrafluoroethylene graft. The patient's postoperative course was complicated by a lymphatic fistula in the groin and impaired wound healing, leading to surgical revisions and flap reconstruction.

Five months after tumour resection, the vascular prostheses had to be replaced with a homograft because of infection. One month later, the patient presented with bleeding in the groin and was readmitted to hospital. During a long and complicated stay, she developed septicemia and died in cardiogenic shock, approximately 15 months after her initial presentation with DVT.

Although her cumulative doxorubicin dose (240 mg/m²) is lower than usual for cardiotoxicity⁵, the combination of septic cardiomyopathy and subclinical anthracycline-induced cardiotoxicity could have caused the low-output cardiogenic shock in this patient's case. At the time of death, no tumour recurrence was evident. The patient's relatives did not consent to a clinical autopsy.

DISCUSSION

Soft-tissue sarcomas comprise more than 50 different histologic subtypes. Synovial sarcomas constitute one of the more common entities and account for approximately 10% of all soft-tissue sarcomas⁶. Histologically, biphasic synovial sarcomas with epithelial-like cells and spindle cells can be distinguished from a monophasic type with only spindle cells. *SYT1-SSX* fusion genes resulting from the characteristic t(X;18) translocation can be observed in up to 95% of all synovial sarcomas, making detection of those fusion genes a diagnostic test for this tumour entity⁷.

The name "synovial sarcoma" was originally coined because of some microscopic resemblance to synovial tissue and the frequent presence of these tumours near joints. However, the name is misleading because the tumour can arise almost anywhere in the body. Multipotent mesenchymal stem cells have been proposed as the origin of the malignant cells⁸.

Primary intravascular manifestations of sarcomas are exceedingly rare. Vascular leiomyosarcomas seem to be most common entity, accounting for 0.7% of all malignant soft-tissue tumours in a study from a German sarcoma reference centre⁹. Other primary intravascular sarcomas such as intimal sarcoma or epithelioid hemangioendothelioma are known from case studies. Primary intravascular synovial sarcomas, as in the present case, are extremely rare. A search of the literature revealed only 9 other documented cases (Table 1). Of the 10 reported patients (including ours), 8 are women. The age of the patients ranges from 16 years to 54 years, with the predominant age group appearing to be 30–40 years. Histologically, the biphasic tumour type seems to be more common (7 of 10 cases). Pain and swelling in a limb were the most common symptoms; 4 patients presented with shortness of breath, indicating PE or protrusion of the tumour into the right atrium.

The vessels most often affected are the proximal femoral and iliac veins (6 of 10 cases). In 2 patients, the tumour was isolated to the inferior vena cava. Involvement of the superior vena cava and upper limb vessels was reported in only 2 patients. Protrusion of the tumour mass into the right atrium is not uncommon, with 3 documented cases. In another 4 patients, including ours, pulmonary emboli were reported, but the presence of tumour emboli was histologically proven in only 1 patient who died shortly after embolectomy¹¹. In the present case, the pulmonary emboli decreased in size after 2 months of anticoagulant treatment, and so we assumed a thrombotic origin and decided against biopsy or removal, which would have put the patient unnecessarily at risk.

Primary treatment options for synovial sarcomas—as for all soft-tissue sarcomas—are wide surgical excision and radiotherapy, often in combination with chemotherapy. Large tumours or tumours in delicate anatomic regions can be treated with preoperative radiotherapy or radiochemotherapy to reduce tumour size and facilitate less-radical surgical techniques. Compared with other soft-tissue sarcomas, synovial sarcomas are regarded as relatively chemosensitive¹⁹. Regimens containing doxorubicin and ifosfamide seem to be the most effective²⁰.

In the present case, neoadjuvant radiochemotherapy with doxorubicin–ifosfamide proved effective and allowed for limb-sparing surgery. However, infection of the vascular grafts caused multiple surgical revisions and hospitalization. An episode of postoperative septicemia ultimately led to the patient's death from a combination of septic cardiomyopathy and anthracycline-induced cardiotoxicity.

SUMMARY

It is well known that malignancies facilitate thromboembolic events by hypercoagulability, pressure, or obstruction of vessels. However, no consensus has been reached on a screening algorithm to detect occult cancer in patients presenting with DVT or PE²¹. The clinician should be aware that cancer might be the underlying cause for thrombosis even in young patients, as in the present case.

The method of choice for diagnosis of DVT is whole-leg compression ultrasonography. In contrast to venography or simple four-point ultrasound examination of the groin and popliteal fossa, whole-leg compression ultrasonography can not only detect thrombosis itself, but also possible underlying pathologies such as soft-tissue tumours. Abnormal vascular ultrasound findings such as "venous ectasia" or "arteriovenous malformation" should always raise suspicion of an intravascular tumour. In the present case, the unusual presence of arterial Doppler signals inside the "thrombus" was a red flag pointing to the diagnosis of intravascular sarcoma. Computed tomography or magnetic resonance angiography is usually the next step, but biopsy should be mandatory.

CONFLICT OF INTEREST DISCLOSURES

We have read and understood *Current Oncology's* policy on disclosing conflicts of interest, and we declare that we have none.

TABLE I Cases of primary intravascular synovial sarcoma reported in the literature

Reference	Age (years)	Sex	Histology	Location	Symptoms
Miettinen <i>et al.</i> , 1987 ¹⁰	34	Female	Biphasic	Left femoral vein	Pain in left hip, swelling in left leg
Shaw and Lais, 1993 ¹¹	31	Female	Biphasic	Inferior vena cava, embolism in both pulmonary arteries	Acute right abdominal pain for 5 hours, cardiac arrest
Robertson <i>et al.</i> , 1998 ¹²	34	Female	biphasic	Left superficial femoral vein	Pain and swelling in left thigh for 2 weeks
White <i>et al.</i> , 2005 ¹³	56	Female	Biphasic	Right external iliac vein	Pain and swelling in right leg
Tong <i>et al.</i> , 2006 ¹⁴	32	Female	Biphasic	Superior vena cava, right internal jugular vein, right proximal subclavian vein, protrusion into right atrium	Pain and swelling in right arm for 2 months
Coen <i>et al.</i> , 2008 ¹⁵	41	Male	Biphasic	Right superficial femoral vein	Sudden dyspnea, swelling in right thigh
Schoneveld <i>et al.</i> , 2012 ¹⁶	32	Female	Monophasic	Right common femoral vein	Sudden dyspnea, swelling in right leg
Tuncer <i>et al.</i> , 2012 ¹⁷	16	Male	Biphasic	Superior vena cava, right atrium	Dyspnea and palpitations
Wise <i>et al.</i> , 2012 ¹⁸	41	Female	Monophasic	Inferior vena cava, right hepatic vein, right atrium	Progressive abdominal pain and distension, swelling in both legs, fatigue
Present report	20	Female	Monophasic	Right superficial femoral vein to common iliac vein, profound femoral vein, great saphenous vein	Progressive dyspnea for 3 days, deep-vein thrombosis 6 weeks earlier, pain in right leg for 12 months

AUTHOR AFFILIATIONS

*Department of Internal Medicine, Cardiology and Angiology, Charité–Universitätsmedizin Berlin, Berlin, Germany; ¹Department of Internal Medicine, Bundeswehr Hospital, Berlin, Germany; ²Pathology Institute, Charité–Universitätsmedizin Berlin, Berlin, Germany.

REFERENCES

- White RH. The epidemiology of venous thromboembolism. *Circulation* 2003;107(suppl 1):14–18.
- Kröger K, Moerchel C, Moysidis T, Santosa F. Incidence rate of pulmonary embolism in Germany: data from the federal statistical office. *J Thromb Thrombolysis* 2010;29:349–53.
- Konstantinides SV, Torbicki A, Agnelli G, *et al.* on behalf of the Task Force for the Diagnosis and Management of Acute Pulmonary Embolism of the European Society of Cardiology (ESC). 2014 ESC guidelines on the diagnosis and management of acute pulmonary embolism. *Eur Heart J* 2014;35:3033–69,3069a–k.
- Zierler BK. Ultrasonography and diagnosis of venous thromboembolism. *Circulation* 2004;109(suppl 1):I9–14.
- Schimmel KJ, Richel DJ, van den Brink RB, Guchelaar HJ. Cardiotoxicity of cytotoxic drugs. *Cancer Treat Rev* 2004;30:181–91.
- Cormier JN, Pollock RE. Soft tissue sarcomas. *CA Cancer J Clin* 2004;54:94–109.
- Saito T. The SYT–SSX fusion protein and histological epithelial differentiation in synovial sarcoma: relationship with extracellular matrix remodeling. *Int J Clin Exp Pathol* 2013;6:2272–9.
- Naka N, Takenaka S, Araki N, *et al.* Synovial sarcoma is a stem cell malignancy. *Stem Cells* 2010;28:1119–31.
- Tilkorn DJ, Hauser J, Ring A, *et al.* Leiomyosarcoma of intravascular origin—a rare tumor entity: clinical pathological study of twelve cases. *World J Surg Oncol* 2010;8:103.
- Miettinen M, Santavirta S, Slätis P. Intravascular synovial sarcoma. *Hum Pathol* 1987;18:1075–7.
- Shaw GR, Lais CJ. Fatal intravascular synovial sarcoma in a 31-year-old woman. *Hum Pathol* 1993;24:809–10.
- Robertson NJ, Halawa MH, Smith ME. Intravascular synovial sarcoma. *J Clin Pathol* 1998;51:172–3.
- White JS, Medlicott SA, Moore R, Temple W. Intravascular synovial sarcoma of the external iliac vein and reconstruction with the superficial femoral vein. *J Vasc Surg* 2005;42:365–7.
- Tong GX, Goldblum JR, Qiu W, *et al.* Primary intravascular synovial sarcoma: a disease of young adult women? Report of a case diagnosed by aspiration biopsy and review of the literature. *Diagn Cytopathol* 2006;34:834–8.
- Coen M, Gagliano T, Tsolaki E, Marchetti G, Marchetti E, Mascoli F. Primary intravascular synovial sarcoma of the femoral vein in a male patient, case report. *Eur J Vasc Endovasc Surg* 2008;36:224–6.
- Schoneveld JM, Debing E, Verfaillie G, Geers C, Van den Brande P. Deep venous thrombosis and pulmonary embolism caused by an intravascular synovial sarcoma of the common femoral vein. *Vasc Endovascular Surg* 2012;46:693–5.
- Tuncer ON, Erbasan O, Golbasi I. Primary intravascular synovial sarcoma: case report. *Heart Surg Forum* 2012;15:E297–9.
- Wise KB, Said SM, Clark CJ, *et al.* Resection of a giant primary synovial sarcoma of the inferior vena cava extending into the right atrium with caval reconstruction under cardiopulmonary bypass and circulatory arrest. *Perspect Vasc Surg Endovasc Ther* 2012;24:95–101.
- Linch M, Miah AB, Thway K, Judson IR, Benson C. Systemic treatment of soft-tissue sarcoma—gold standard and novel therapies. *Nat Rev Clin Oncol* 2014;11:187–202.
- Spurrell EL, Fisher C, Thomas JM, Judson IR. Prognostic factors in advanced synovial sarcoma: an analysis of 104 patients treated at the Royal Marsden Hospital. *Ann Oncol* 2005;16:437–44.
- Gaitini DE, Brenner B. Do we need a cancer screening in patients with idiopathic deep vein thrombosis? *Ultraschall Med* 2008;29(suppl 5):220–5.